

Figures

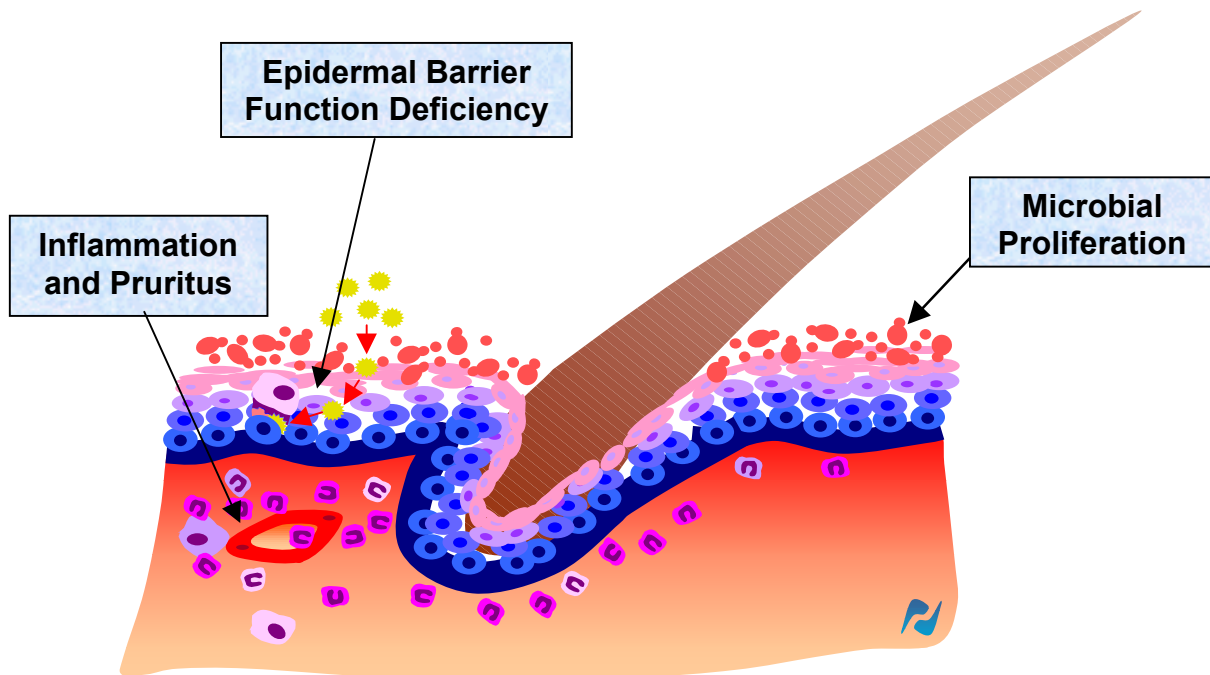


Fig. 1 : Main pathogenic features of canine atopic dermatitis

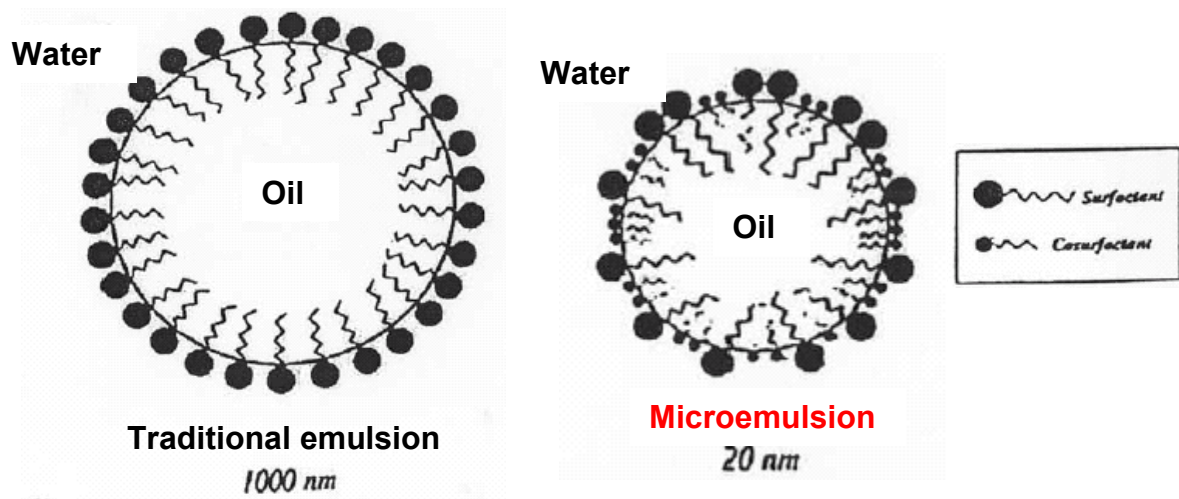


Fig. 2 : Emulsion and microemulsion ultrastructures

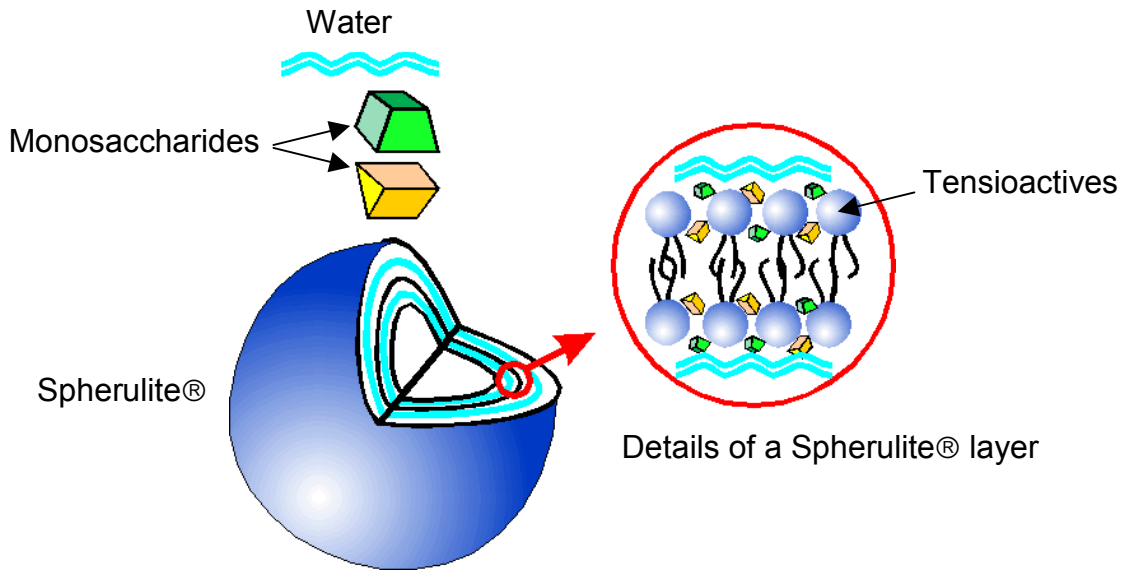


Fig. 3 : Non-ionic Spherulite® ultrastructure

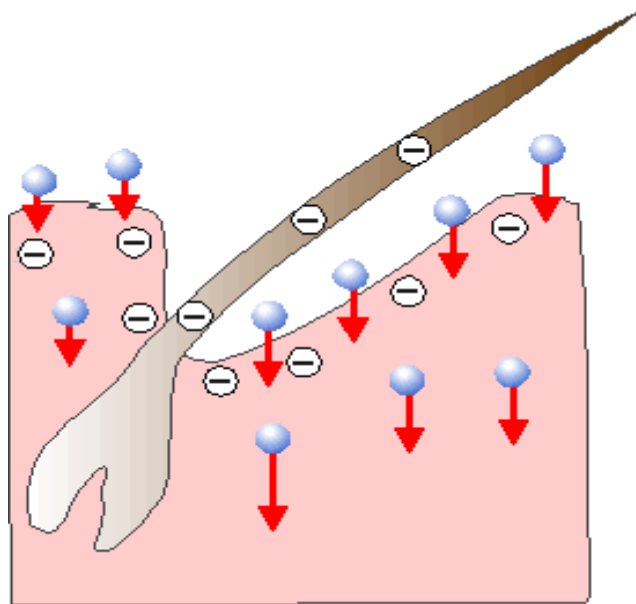


Fig. 4 : Percutaneous diffusion of Non-ionic Spherulites®

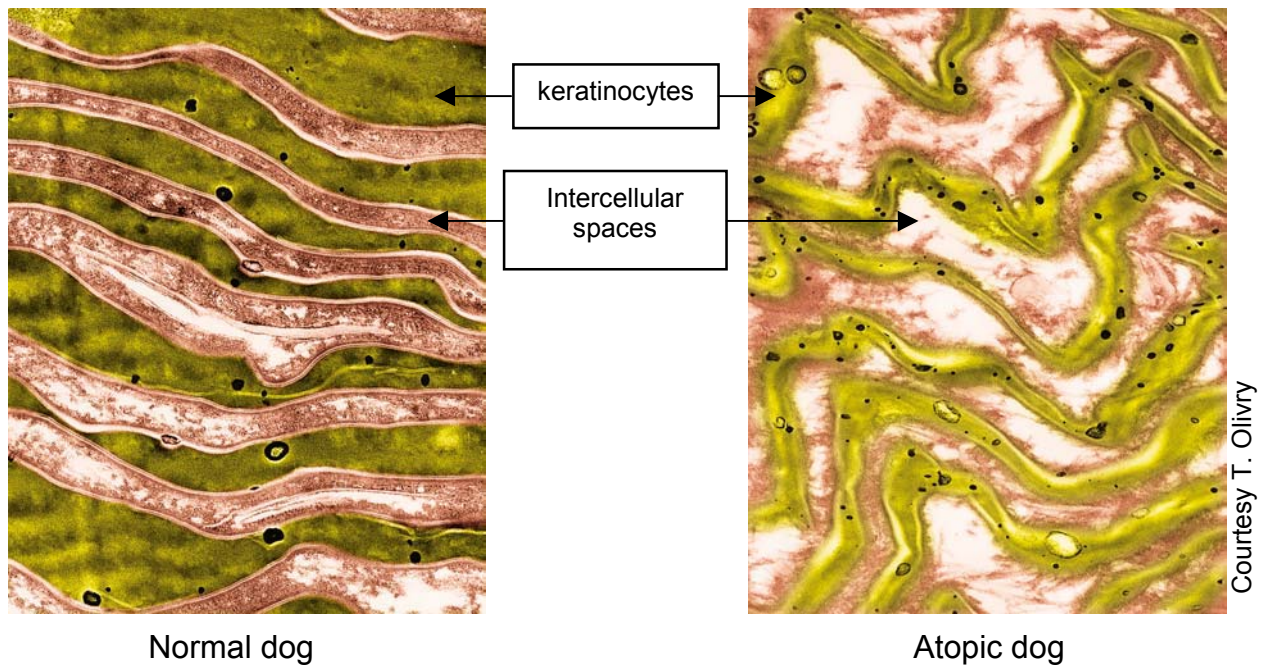


Photo 1: Electron microscopic observation of canine *stratum corneum* in healthy and atopic dogs

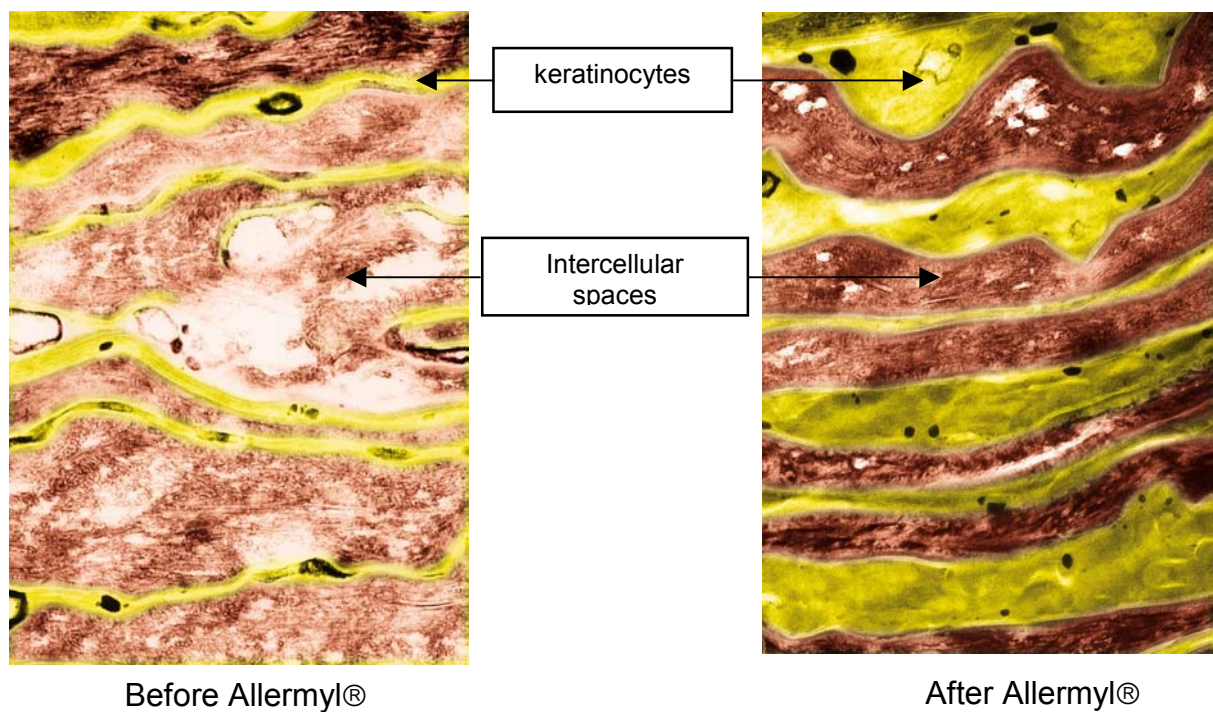


Photo 2: Electron microscopic observation of canine *stratum corneum* in atopic dogs before and after 2 weeks of Allermyl® treatment

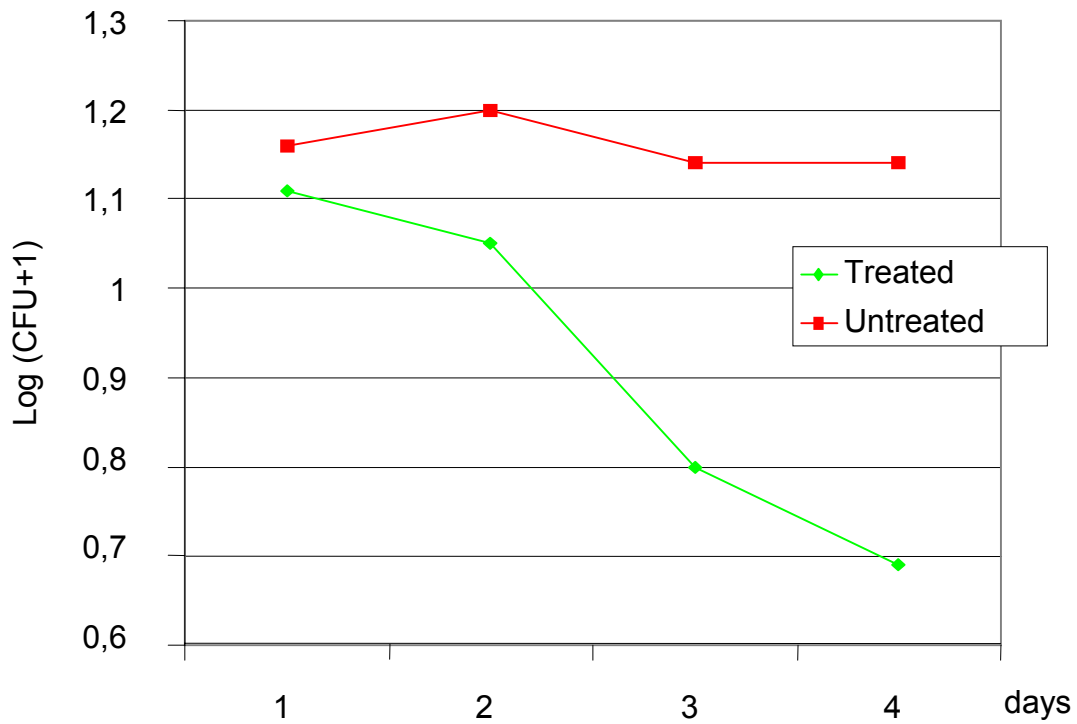


Fig. 5: Cultures of *Malassezia* from the neck of dogs treated or not with a piroctone olamine shampoo

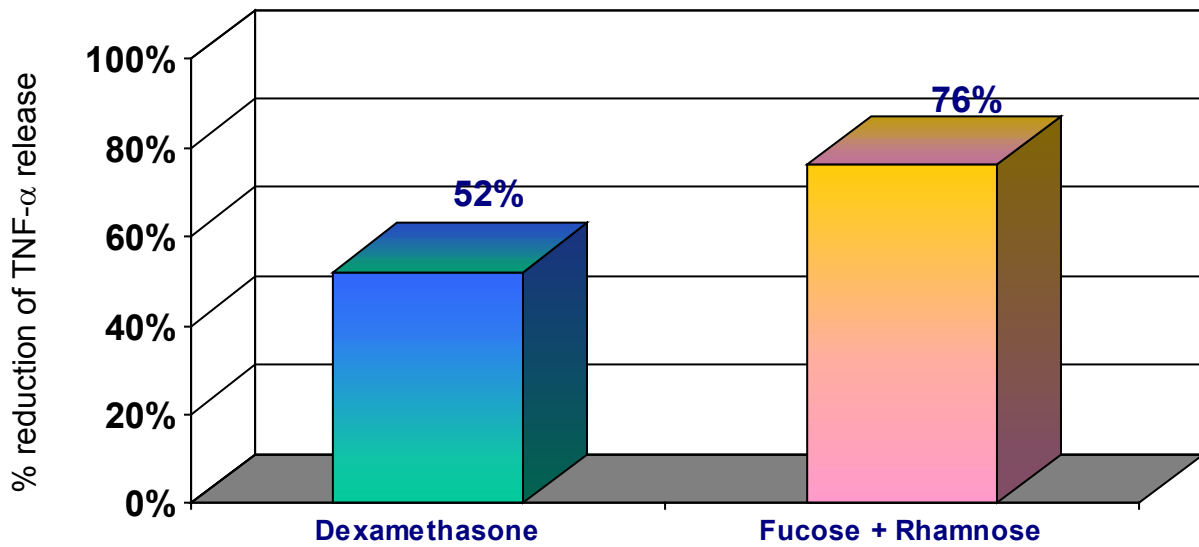


Fig. 6: Relative reduction of TNF- α secretion by activated canine keratinocytes *in vitro*

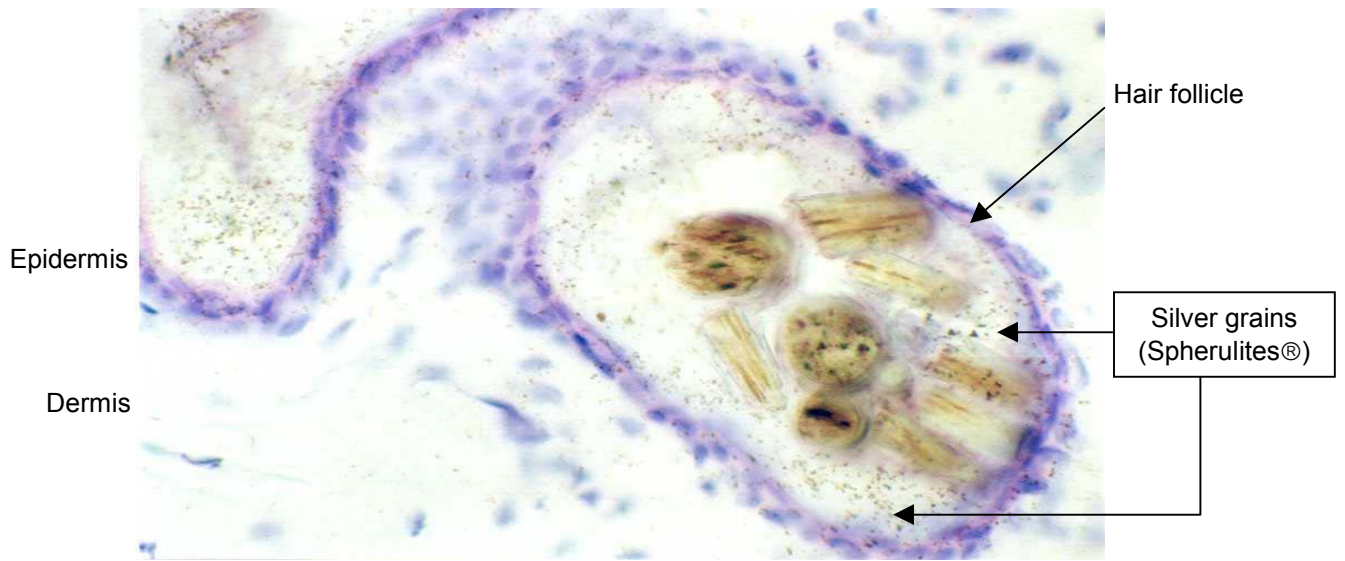

Photo 3: Distribution of ^{14}C -labelled non-ionic Spherulites® on canine skin biopsies